

CRYOSURGERY IN THE TREATMENT OF SKIN DISORDERS IN REPTILES

J. S. BAXTER¹ AND R. MEEK²¹2 Rose Avenue, Horsforth, Leeds, U.K.; ²8 Mountfield Road, Waterloo, Huddersfield, U.K.

(Accepted 11.5.87)

ABSTRACT

Cryosurgery has been used for the treatment of skin disorders in two lizards and a chelonian. The results of this and a previous application (Green *et al.*, 1977) indicate that cryotherapy may be a valuable surgical tool for use in reptilian veterinary science.

INTRODUCTION

Cryosurgical techniques, employing ultra low temperatures to destroy unwanted tissues, have a long history in medical practice (Baxter, 1977a; 1977b). Reports, however, of their application in the treatment of reptilian ailments are rare indeed. In a review (Cooper & Jackson, 1981) only a single reference was cited for the use of cryotherapy on a reptile (Green *et al.*, 1977). This dealt with the treatment of necrotic stomatitis in a python (*Python molurus*) using a liquid nitrogen spray (see Baxter, 1977b). The results of this application lead the authors to suggest cryotherapy as an alternative to conventional methods for treating chronic lesions of the reptilian integument and buccal cavity. However, since this report no further descriptions of cryosurgery on reptiles have appeared in the literature, although Frye (1981) suggested the possibility of using cryosurgery in cases where excision is inappropriate. This paper gives details of the case histories of its use in the treatment of skin disorders in two lizards and a chelonian.

METHODS AND MATERIALS

SPECIMENS

1. *Lacerta viridis*. A female about 4.5 years old was brought to the surgery of J.S.B. with a large irregular keratinised growth immediately anterior to the left shoulder area (Fig. 1a). The growth resembled the papillomas of the skin often observed in Lacertid lizards (e.g. Koch, 1904; Stolk, 1953; Lopez & Bons, 1981), although their most frequent occurrence appears to be in *L. viridis* (Blanchard, 1890; Plehn, 1911; Schnabel, 1954; Raynaud & Adrian, 1976; Harshbarger, 1965-1977). The owner reported that it has developed over the previous 18 months and was now at the stage where it seriously interfered with limb movement.

2. *Tupinambis teguixin*. An adult female on display at the Department of Pure & Applied Zoology, University of Leeds with a skin lesion on the left rear foot. This had been present for approximately 3 weeks and the only previous treatment had been the protection of the area from abrasion by the application

of an elastoplast dressing. There was a scale deficit of approximately 10mm x 8mm, exposing underlying tissue and the margins of the lesion were under-run. The whole area exhibited a degree of 'sub-cutaneous' oedema.

3. *Terrapene carolina*. A female belonging to a local pet shop had a tense, inflamed, dome-shaped swelling, some 10mm in diameter (Fig. 2a). This was diagnosed to be the result of an infection behind the tympanic membrane of the ear and is a common site for abscess formation in chelonians (Jackson & Lawrence, 1985).

ANAESTHETIC TECHNIQUE

1. *L. viridis*. After a totally ineffective attempt to produce anaesthesia with an 0.05ml/m injection of Saffan (Alphaxalone/Alphadolone 15mg/ml/kgm) the animal was anaesthetised using the gas box principle. A gauze swab was taped to the lid of a cylindrical glass container. Four millilitres of Fluothane was injected into this pad and the lid replaced over the chamber into which the lizard was placed. Between 5-8 minutes the animal was deeply sedated and easily handled but still showed signs of pain sensation. We replaced the lizard in the chamber and an overall time of around 19 minutes was assessed to be sufficient for surgical anaesthesia. However, when cryosurgery was commenced it was found necessary to 'top-up' the anaesthetic by placing the end of a corrugated gas-pipe over the lizard's nose and feeding it a 3 per cent concentration of Fluothane in a 50/50 oxygen nitrous oxide mixture.

2. *T. teguixin*. Due to the superficial nature of this lesion and the relatively pain-free qualities of cryosurgical technique, it was decided that no anaesthesia was required in this case.

3. *T. carolina*. With due consideration to the site of the lesion and its inaccessibility if the animal should withdraw into its shell, adequate anaesthesia was deemed essential. The animal weighed 290 grams and using a recommended dose of 60mg/kg (Green, 1979) 20mgm of Ketamine was injected, using a twenty-five gauge needle, into the quadriceps group of muscles. Although adequate sedation was achieved by 30 minutes, depth of anaesthesia for surgical purposes was reached at closer to 69 minutes post administration.

RESULTS

L. viridis. A PCG 12 nitrous oxide cryo-gun was used to freeze the flattened base of the tumour as it was pulled laterally. Three freeze-thaw cycles were effective in achieving an ice-ball across the whole tissue thickness of the base and extending one or two mm into normal body tissue. After freezing, a crack appeared in the upper part of the tumour making it possible to de-bulk the upper third. The portion removed was submitted for pathology. The exposed base bled a little too freely and following further freezes with a flat faced cryoprobe, the base was ligated to prevent post-operative haemorrhage.

Healing was complete in approximately 4 weeks leaving only a fine grey scar (Fig. 1). Pathology confirmed the lesion to be a papilloma with heavy surface keratinisation. After approximately six months, the patient was represented with a small regrowth of the papilloma on the upper right quadrant of the scarred area. The lesion measured 2mm in diameter and because of the painfree properties of cryosurgical technique in most situations we were able to refreeze the regrowth without anaesthesia, applying a triple freeze-thaw cycle using a nitrous oxide cryogun (PCG 12). In the ensuing three months there has been no recurrence but since cryosurgery can be repeated without major stress to the animal the technique is admirably suited to the treatment of such cases.

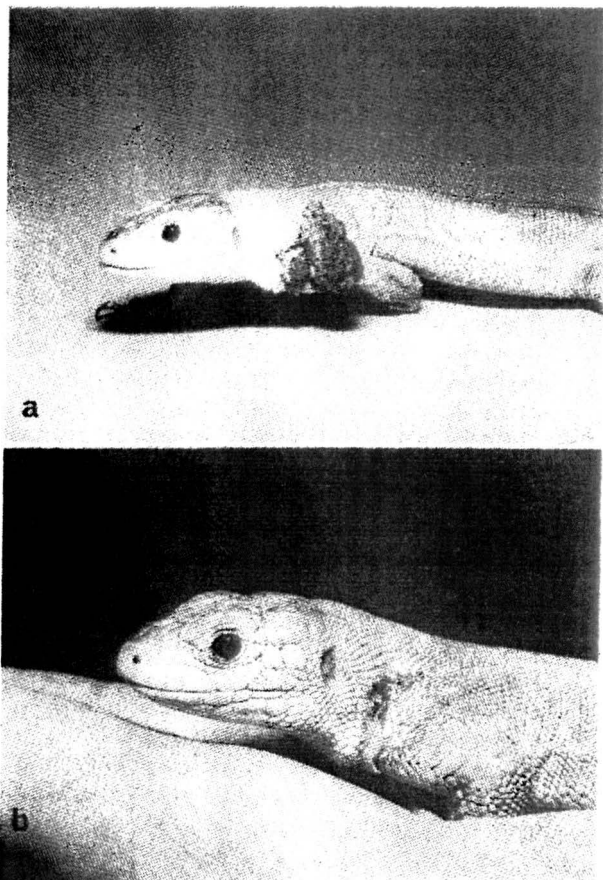


Fig. 1 A green lizard *Lacerta viridis* with a large keratinised papilloma (Fig. 1a). The same animal is shown post-operatively in Fig. 1b; only a minor grey scar marks the area of the lesion.

T. tequixin. A flat probe on the Spembyl PCG 12 cryo-gun was used to destroy the diseased and damaged tissue. The moist nature of the lesion made this freezing technique most effective. Four freeze-thaw cycles were used and following the final thaw, the area was dusted with an antiseptic powder to prevent surface infection. Finally the lesion was lightly covered with a gauze and elastoplast dressing. Four days after the operation the lesion had formed a dry black eschar and from then healing proceeded uneventfully to completion in approximately four weeks. There was no pathological examination made of this lesion. The lizard has been regularly examined over a nine month post-operative period and there has been no recurrence at the site of the original lesion.

T. carolina. The swelling was incised and a caseous core together with a quantity of white creamy purulent fluid expressed (Fig. 2). Swabs were taken from inside the resulting cavity and submitted for bacteriological examination. In the majority of cases, the expression of purulent material together with the establishment of adequate drainage would be sufficient to achieve a cure. In this case however, it was decided that the careful application of a nitrous oxide cryoprobe would contribute significantly to the outcome. Certainly, the cryo-surgical destruction of the infected lining of the cavity and the resultant pain reducing qualities of the technique could only be useful. This was done using four freeze-thaw cycles with the PCG 12 cryo-gun.

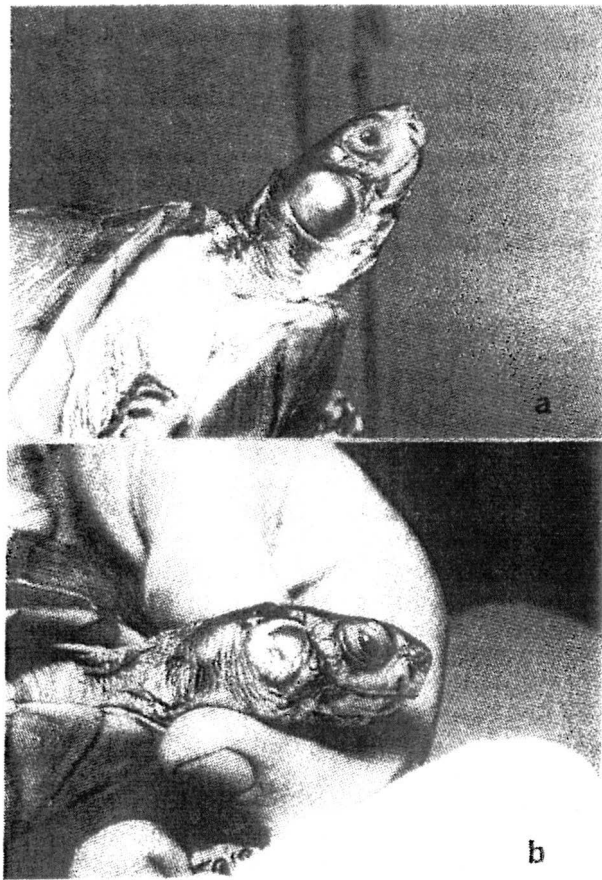


Fig. 2 A tense inflamed lesion on the neck of a *T. carolina* (2a). The lesion immediately after drainage and treatment by cryosurgery (2b).

Healing was again uneventful and the bacteriological examination revealed a profuse growth of beta-haemolytic streptococci.

DISCUSSION

Historically the development and application of cryo-surgery in veterinary science has concerned the physiology of endothermic vertebrates, however, as the results of this paper and the previous application by Green *et al.*, (1977) show it would appear to be an attractive addition to the armoury against accessible disease conditions of reptiles. Cryo-surgery, the use of extremely low temperatures to destroy undesirable tissue, can basically be considered to be nothing more or less than controlled frost-bite in which the frozen tissue dies and is removed by the body itself — either by absorption or sloughing (usually the latter). With its qualities of virtually painless application, lack of haemorrhage, minimal scarring and no need for stitches it could have a lot to offer the field of reptilian medicine, thus for ectotherms and endotherms, it may be the cold cure that really works.

REFERENCES

- Baxter, J. S. (1977a). Machinery of veterinary cryosurgery. *British Journal of Small Animal Practice* **19**, 27-34.
- Baxter, J. S. (1977b). Techniques of veterinary cryosurgery. *British Journal of Small Animal Practice* **19**, 35-41.
- Blanchard, R. (1890). Sur une remarquable dermatose causée chez le lézard vert par un champignon du genre *Selenosporium*. *Mémoires Societe Zoologique de France* **3**, 241-255.
- Cooper, J. E. and Jackson, O. F. (1981). *Diseases of the Reptilia* (2 vols.) London, Academic Press.
- Fyre, F. L. (1981). *Biomedical and surgical aspects of captive reptile husbandry*. Kansas, V.M. Publishing.
- Green, C. G. (1979). *Animal Anaesthesia*. London, Laboratory Animals Ltd.
- Green, C. G., Cooper, J. J. and Jones, D. M. (1977). Cryotherapy in the reptile. *Vet. Rec.* **1977**, 529.
- Harshbarger, J. C. (1965-1977). No. 482, 1389, 1524, 1821 in *Registry of Tumors in Lower Animals. Activities report registry 1965-1977*. Smithsonian Institute Washington D.C.
- Jackson, O. F. and Lawrence, K. (1985). Reptiles. In *Manual of exotic pets*. Eds. Cooper, J. E., Hutchinson, M. F. Jackson, O. F. and Maurice, P. J. Cheltenham, British animal veterinary association.
- Koch, M. (1904). Demonstration einiger Geschwulste bei Teiren Verhandlungen der Deutschen *Pathologischen Gesellschaft* **7**, 136-147.
- Lopez, A. and Bons, J. (1981). Studies on a case of papillomatosis in the eyed lizard *Lacerta lepida*. *British Journal of Herpetology* **6**, 123-125.
- Plehn, M. (1911). Über Geschwulste bei niederen Wirbeltieren. *2e Conference Internationale Etude Cancer*, 221-242.
- Raynaud, A. and Adrian, M. (1976). Lésions cutanées à structure papillomateuse associées à des virus chez le lézard vert (*Lacerta viridis* Laur). *C.R. Acad. Sci. Paris* **283, D**, 845-847.
- Schnabel, R. (1954). Papillome an einer Smaragdeidesche (*Lacerta viridis*). *Zoologische Garten* **20**, 270-278.
- Stolk, R. (1953). Hyperkeratosis and carcinoma planocellulare in the lizard, *Lacerta agilis*. *Koninklijke Nederlandash Akademie von Wetenschappen C*, **56**, 157-163.